Healing of the retinal pigment epithelium (RPE) imaged "in vivo" in patients with RPE tears.

Randev Mendis[1,2] and Noemi Lois[2]

[1]Canberra Hospital, ACT Health Directorate
[2]NHS Grampian University Hospitals-NHS Trust and University of Aberdeen

Left eye color fundus

Left eye FFA early

Left eye FFA late

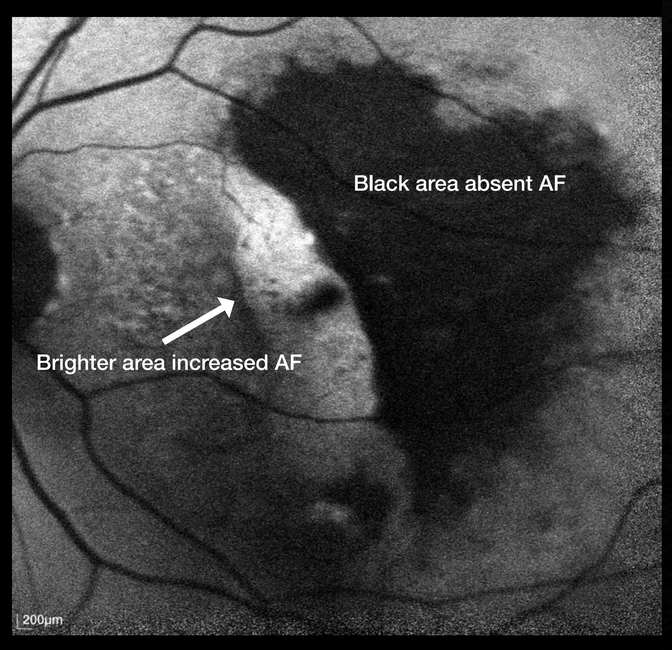

★AF image of RPE tear

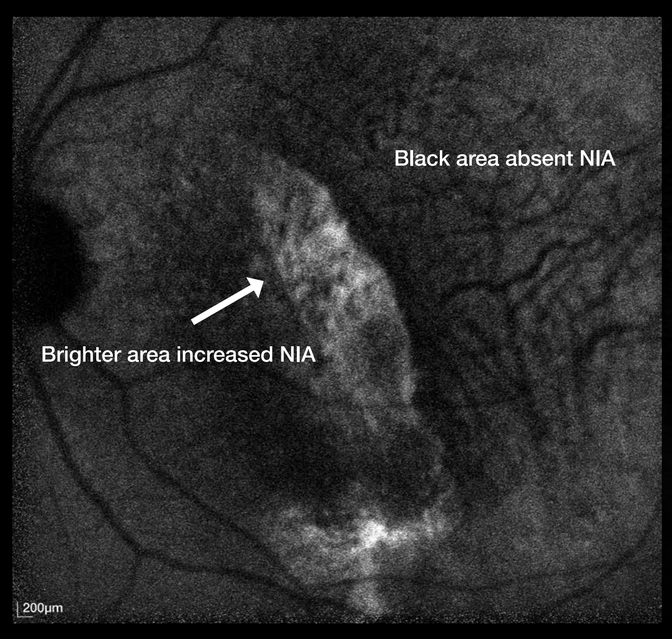

★★ NIA image of RPE tear

Introduction

To describe findings on fundus autofluorescence (AF) in a group of consecutive patients with retinal pigment epithelial (RPE) tears and to report on functional and anatomical outcomes following the occurrence of this event.

Methods

Patients were identified through an electronic database; all RPE tears that occurred between 01/03/2008-01/03/2011 were included. AF images were assessed qualitatively and quantitatively. There was an area of reduced AF signal corresponding to the area debrided of RPE. This area was measured on baseline and last follow-up 30° AF image frames in all patients with Heidelberg HRA-2 image analysis software. The change in the reduced AF area was calculated by subtraction, from baseline the last follow-up reduced AF signal area. The resultant, reduced, AF signal area was used to determine recovery or progression.

Recovery was defined as a reduction in the area of reduced AF signal and progression was defined as an increase in the area of reduced AF signal.

Results

Fourteen eyes of 13 patients (mean age 82) with RPE tears followed for a median of 11.5 months (range, 1-39) were included in this study. The median Log-MAR VA pre/post RPE tear was 0.5 (6/12) and 0.8 (6/36) respectively.

A typical RPE tear on AF imaging (figure★AF image of RPE tear) had an area of reduced AF signal (black area-debrided of RPE) and increased AF signal (bright area-rolled, torn RPE). In near infra red autofluorescence (NIA) imaging (figure★★ NIA image of RPE tear) the pattern was similar with a reduced and increased NIA signal corresponding to areas of debrided RPE and torn-rolled RPE, respectively. There was recovery of AF signal area in 10 eyes (median 1.3, range- 0.03-6.78) and progression of the reduced AF signal area in 4 (median 0.7, range-0.11-5.58).

Conclusion

A characteristic pattern of fundus AF was observed in RPE tears that allowed for non-invasive diagnosis of this condition. Recovery of the AF signal around the RPE tear was noted in majority of the cases. These results may indicate a degree of 'healing' of the RPE defect possibly by proliferating and sliding RPE cells.

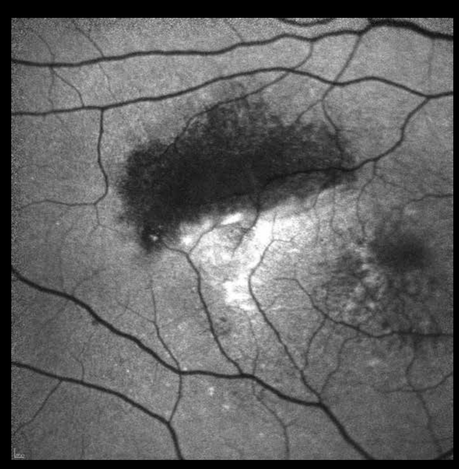

Patient 1: 8 months apart

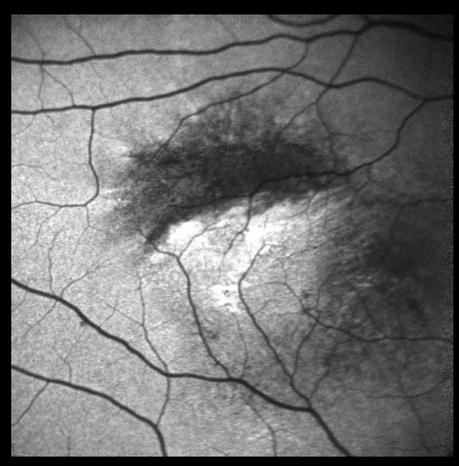

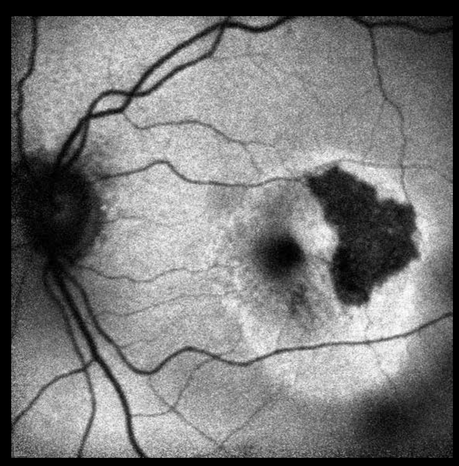

Patient 2: 4 months apart

Patient 3: 22 months apart